

Site(s)	Document Number	Approved	Page 1 of 9
All Sites	VAS-DP-1	Kelly Swagell	
Title		Version Date	Version Number:
Carotid and vertebral ultrasound		Dec 2021	1.2

Scope & purpose

Extracranial cerebrovascular duplex ultrasound examinations are carried out to assess for the presence of pathology and the haemodynamic status of the common carotid, internal carotid, external carotid and vertebral arteries.

Common indications for performance of this examination can include:

- Transient ischemic attacks (TIA)
- Amaurosis fugax
- Carotid bruit
- Cerebrovascular Accident (CVA)
- Follow-up of known carotid stenosis
- Post intervention follow-up e.g. carotid endarterectomy, stent or bypass
- Trauma in the distribution of the carotid artery e.g. suspected dissection, arteriovenous fistula or pseudoaneurysm
- Pulsatile neck masses
- Evaluation of suspected subclavian steal syndrome

Personnel

Clinical vascular scientists (CVS), including trainees.

Principles / performance characteristics

To determine the presence or absence of carotid and vertebral artery disease, including anatomical variants; using B mode, colour and spectral Doppler.

Service users & background

Patients with a suspected TIA or stroke may be referred for a carotid scan as part of their work up, in conjunction with other imaging modalities. Carotid surgery or stenting is a possible endpoint of this pathway and current recommendations indicate that this should be undertaken within two weeks of the TIA. Therefore, if this diagnostic test is appropriate it should be carried out urgently, preferably within 24 hours of the onset of symptoms (ref 1). This diagnostic investigation aims to establish if extracranial disease is a possible cause for their symptoms and if the patient's disease is amenable for surgical intervention.

There are few contraindications for carotid duplex ultrasound; however, limitations may include the following:

- Obesity or short, thick muscular necks
- Dressings, open wounds, staples, haematoma etc.
- Acoustic shadowing
- Patients who are unable to lie flat
- Patients who are unable to cooperate due to reduced cognitive functions e.g. Alzheimer's or dementia and through involuntary movements
- Examinations undertaken at the patient's bedside may be limited due to equipment and room dimensions

Site(s)	Document Number	Approved	Page 2 of 9
All Sites	VAS-DP-1	Kelly Swagell	
Title		Version Date	Version Number:
Carotid and vertebral ultrasound		Dec 2021	1.2

- Patient discomfort

Facilities, equipment & special supplies

Duplex ultrasound machine with both linear and curvilinear transducers available. There should be a selection of transducers delivering a wide range of frequencies (high and low).

Ultrasound gel to provide a couplant between transducer and patient.

Examination couch should be height adjustable. The CVS's chair should provide good lumbar support, be height adjustable and allow for the CVS to move close to the examination couch.

Cleaning materials should be available in line with local and manufacturer's guidelines. These are available either in each procedure room or located in the laboratory store room.

Calibration

Across all sites annual calibration and safety checks of the ultrasound equipment are performed by Clinical Engineering (Trust contract with GE Healthcare).

Quality control

Second opinions from vascular scientist colleagues are requested routinely if clarification is sought.

Trainee vascular scientists have all carotid scans checked until they are signed off by a senior colleague for competency.

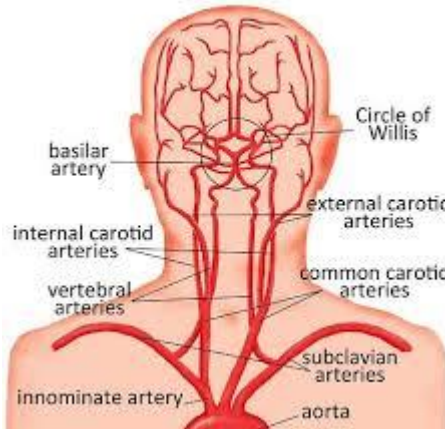
Environmental & safety controls

Infection control procedures followed in accordance with Trust infection control and risk assessment policies – Please see 'Personal Protective Equipment (PPE) for infection prevention and control' policy, 'Hand Hygiene' policy and 'Staff Risk Assessments' which are all available through the Trust Intranet.

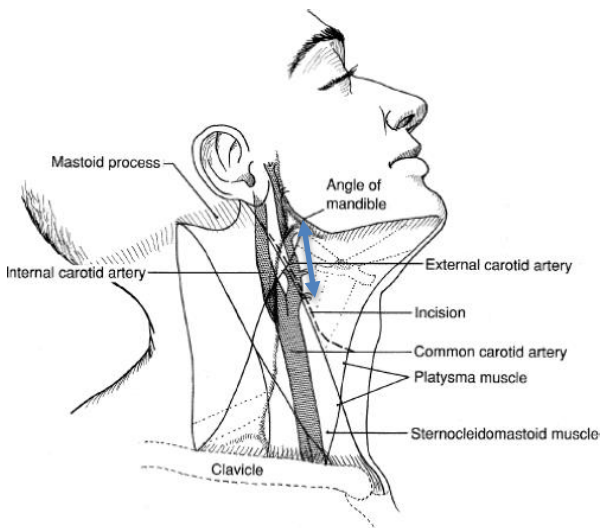
Tristel wipes are for cleaning the ultrasound machines and probes after patient use. Universal Clinell wipes are for cleaning all other equipment. Where high risk infection presents or post-op wounds are present use probe covers with sterile gel or Tegaderm dressings, in addition to routine cleaning.

Site(s)	Document Number	Approved	Page 3 of 9
All Sites	VAS-DP-1	Kelly Swagell	
Title		Version Date	Version Number:
Carotid and vertebral ultrasound		Dec 2021	1.2

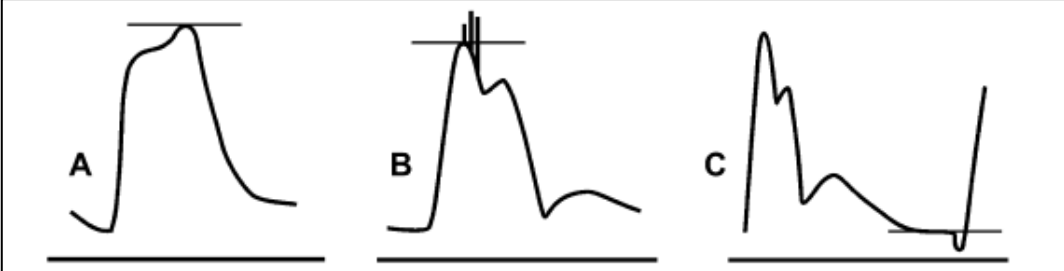
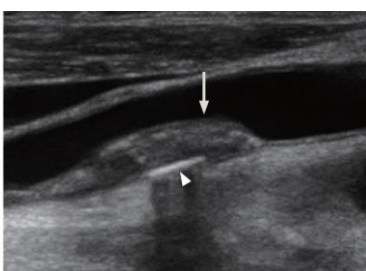
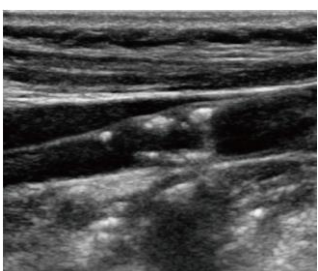
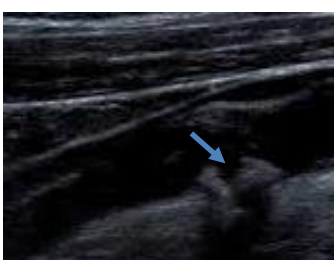
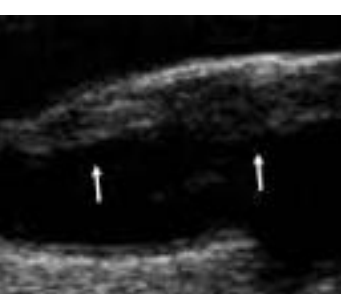
Carotid ultrasound procedure (ref 1)

	Preceding document: <i>VAS-MP-6 Patient management</i>
1.	The patient is asked to adjust their clothing to expose the neck area and remove jewellery if necessary. Ideally, the patient is examined in the supine position with their head/neck positioned in such a manner that allows the CVS maximum access to the vessels to be examined. On rare occasions, it may be necessary to scan the patient in a chair if they have limited mobility and are unable to transfer.
2.	<p>The scan is performed in both colour flow imaging and B-mode in both longitudinal and transverse planes. The CCA is scanned from as proximal as possible (origin on the right), then distally to the bifurcation and then as far distally as possible into the internal carotid artery (ICA). The external carotid artery (ECA) is imaged proximally. The vertebral artery is assessed in the mid neck, where visible. The right proximal subclavian artery is assessed, origin when possible.</p>  <p><i>Figure.1 Image taken from Children's Wisconsin (2020) (ref 2)</i></p> <p>The machine controls should be optimised continually throughout the scan to obtain the best image to aid with diagnosis.</p>
3.	Peak and end diastolic velocities of the distal CCA, the proximal ECA and the proximal ICA are measured bilaterally and documented on the diagram. A peak systolic velocity (PSV) and waveform should be measured in the right proximal subclavian artery. Vertebral artery peak and end diastolic velocities are measured and direction of flow identified. In the presence of reversed or partially reversed flow, the subclavian artery should be examined bilaterally and bilateral blood pressures recorded. If a significant stenosis is identified in the right subclavian artery (regardless of vertebral artery waveforms) the left subclavian artery should also be imaged proximally and bilateral blood pressures should be recorded (ref 3).

Site(s)	Document Number	Approved	Page 4 of 9
All Sites	VAS-DP-1	Kelly Swagell	
Title		Version Date	Version Number:
Carotid and vertebral ultrasound		Dec 2021	1.2

4.	In the presence of a significant stenosis (>50%) located in the CCA the velocities pre-stenosis and within stenosis are measured and documented. See CCA grading criteria in reporting section (table 1).
5.	<p>In the presence of a significant stenosis (>50%) located in the ICA the following measurements are made:</p> <ul style="list-style-type: none"> The highest peak systolic velocity and corresponding end systolic velocity are recorded and documented If symptomatic, the length of the plaque extension into the ICA from the bifurcation is measured. The distance of the bifurcation apex to the angle of the mandible is also measured (demonstrated by the blue arrow on figure 2) and the line of the jaw is drawn on the report. A distal ICA PSV & EDV.  <p><i>Figure 2. Image taken from Basic medical key (2020) (ref 4)</i></p>
6.	There is no consensus document for ECA grading criteria, therefore B mode diameter reduction and peak systolic velocities are used to guide grading stenosis.
7.	The ICA and ECA should be clearly distinguished. If a >50% stenosis is detected in the ECA or ICA a temporal tap (tapping over the ipsilateral superficial temporal artery to detect a change in spectral waveform) must be performed, then documented on the report. A second opinion from a senior colleague must be obtained if there is any uncertainty.
8.	When measuring velocities the Doppler angle should be 60 degrees or less and parallel with the flow of blood. It should always be recorded in longitudinal plane. The joint recommendations document (ref 5) gives detailed information on how velocity measurements should be made, including control settings such as Doppler gain and the placement of the velocity cursor in order to make measurements consistent (fig 3).

Site(s)	Document Number	Approved	Page 5 of 9
All Sites	VAS-DP-1	Kelly Swagell	
Title		Version Date	Version Number:
Carotid and vertebral ultrasound		Dec 2021	1.2

	 <p><i>Figure 3. Showing the correct placement of the velocity cursor (A) when the systolic peak is delayed, (B) when there is spike turbulence on the systolic peak, and (C) when the foot of the next systolic peak dips below the end-diastolic velocity (ref 5).</i></p>
9.	<p>Any disease noted in the ICA is classified into plaque characteristics (smooth, irregular, dense, soft, mixed, calcified and/or ulcerated).</p> <div style="display: flex; justify-content: space-around; align-items: flex-start;"> <div style="text-align: center;">  Smooth, mixed plaque </div> <div style="text-align: center;">  Irregular, calcified plaque </div> <div style="text-align: center;">  Ulcerated plaque </div> </div> <div style="text-align: center; margin-top: 20px;">  Soft plaque </div> <p><i>Figure 4. Departmental ultrasound images depicted various plaque characteristics.</i></p>
10	<p>If required, the intimal medial thickness is measured ~1.0cm proximal to the carotid bifurcation on the posterior medial wall and documented in cm (normal <0.07cm, ref 6). If plaque is noted on the posterior wall an IMT measurement can be taken from the anterior wall. If no plaque is detected throughout the carotid arteries but generalised increased IMT is noted, this may be an occasion when IMT is reported. Wall thickening should be draw on the diagram.</p>
11.	<p>For patients with poor access, or who are moving excessively, it is acceptable to not record velocities if genuinely not possible, and describe any plaque on its colour and</p>

Site(s)	Document Number	Approved	Page 6 of 9
All Sites	VAS-DP-1	Kelly Swagell	
Title		Version Date	Version Number:
Carotid and vertebral ultrasound		Dec 2021	1.2

	B-mode appearance. This would be considered a very rare occurrence and only after asking for assistance from a colleague.
12.	<p>For pre-op marking of the carotid prior to endarterectomy, the operation side must be rescanned in full by a different CVS (where possible) for quality control, and a new report produced. When marking the neck the pillow should be removed and the head slightly tilted up and turned to face the other way. . Using a blue marking pen, mark on the patient's neck the level of the bifurcation in transverse and the extent of the ICA plaque in longitudinal - an inverted 'T' should be apparent. If significant plaque extends into the CCA, extend the blue line into the CCA - a '+' sign will be apparent. If significant plaque is in the CCA only, a 'T' will be apparent.</p> <p>On a copy of the new report, a replica of the blue lines drawn on the patient should be drawn on the report with blue pen. The report then needs to be signed and dated in the blue pen.</p>
	Subsequent documents: <i>VAS-MP-6 Patient management, VAS-MP-1 Results processing</i>

Reporting

The diagrammatic report is a record and interpretation of observations made during the carotid duplex ultrasound examination; it should be written by the CVS undertaking the examination.

The report should include correct patient demographics, date of examination, examination type, the name and status of the CVS and any clinical history deemed relevant.

The report is the diagram. All disease or variable anatomy must be drawn on the diagram together with the PSV and EDV for ICA, CCA, ECA and vertebral arteries. The PSV and waveform of the right subclavian artery should be documented.

Comment on any dissections, abnormal distal resistance, or any unusual pathology on the report.

For the grading of CCA stenoses, velocity ratios are used (see table 1). Document pre and post PSVs, the PSVR and the percentage stenosis on the report.

Table 1: Arterial velocity grading criteria.

Peak Systolic Velocity Ratio (Vs/Vp)	Reported stenosis
< 2	<50% stenosis
2	~50% stenosis
2.1-3.9	50-74% stenosis
4	~75% stenosis
>4	>75% stenosis

Site(s)	Document Number	Approved	Page 7 of 9
All Sites	VAS-DP-1	Kelly Swagell	
Title		Version Date	Version Number:
Carotid and vertebral ultrasound		Dec 2021	1.2

No flow detected

Occluded

Vs = Highest PSV at site of stenosis, Vp = pre-stenosis PSV (ref 7).

For grading of ICA stenoses please refer to table 2. All the different grading criteria can be used to come to a conclusion on the percentage stenosis. These should all be calculated and documented in the written report. St Mary's ratio should not be used in the presence of low end diastolic flow (<10cm/s), absence of end-diastolic flow or retrograde end diastolic flow, or if the patient has known aortic valve disease (ref 5).

Table 2: ICA stenosis velocity grading criteria (ref 1 & 5)

Percentage stenosis (NASCET)	ICA PSV (cm/sec)	Peak systolic velocity ratio ICA PSV / CCA PSV	St Mary's Ratio ICA PSV / CCA EDV*	ICA EDV (cm/sec)**
<50%	<125	<2	<8	<40
50-59%	>125	2-4	8-10	40-100
60-69%			11-13	
70-79%	>230	>4	14-21	>100
80-89%			22-29	
>90 but less than near occlusion	>400	>5	>30	
Near occlusion	High, low-string flow	Variable	Variable	Variable
Occlusion	No flow	Not applicable	Not applicable	Not applicable

*Caution to be used when grading 50-59% stenosis using the St Mary's Ratio, evidence is not as strong for this grading bracket (ref 8, 9,10)

** Additional criteria suggested by the SVT professional performance guidelines (ref 1)

Diameter reduction measurements in the ICA can be made on the B-mode image if velocity criteria is ambiguous, but are not required routinely to grade significant stenosis; however these will be dependent on appropriate gain selection and choice of imaging plane and should be according to the NASCET method (figure 5, ref 5). Diameter measurements made in the bulb should be made using the NASCET method to correlate with the velocity criteria used, (unless clearly stated as being ECST measurements). ECST diameter reduction measurements are valid in the presence of large ICA bulb (>10mm) or thrombus. If denoting a diameter reduction measurement on the report it should be written on the side of the report beside the diagram and the following terminology can be used 'x-x% DR NASCET/ECST'. The word 'visual' should be avoided.

Site(s)	Document Number	Approved	Page 8 of 9
All Sites	VAS-DP-1	Kelly Swagell	
Title		Version Date	Version Number:
Carotid and vertebral ultrasound		Dec 2021	1.2

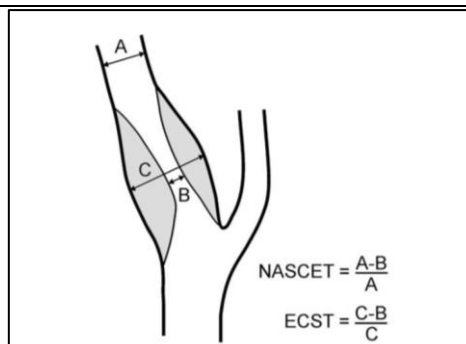


Figure 5. Diagram of stenosis showing the NASCET and ECST methods of calculating percentage diameter stenosis. NASCET used the high distal ICA for measuring distance A (ref 5)

Grading a <50% stenosis:

- 0-29% can be eyeballed visually and graded <10%, 10-19%, 20-29%. NASCET diameter reduction measurements can be used if required.
- 30-49% should be measured using NASCET diameter reduction measurements and graded 30-39%, 40-49%.
- If all velocity criteria suggest <50% stenosis and you are unable to measure the plaque accurately (i.e. views are poor due to heavy calcification or the plaque is irregular) it is acceptable to grade as '<50%' in the box and note minor plaque in the conclusion.

If all velocity criteria are used and suggest <50% stenosis but the NASCET diameter reduction measurement is >50%, it can be used to assist with the grading of the stenosis but the haemodynamic criteria bears more weight than diameter reduction. Not only due to the inaccurate nature of diameter reduction measurements but when you take all the measurements into consideration (velocities and DR) the majority of the measurements would grade <50% NASCET and this should be reflected in your conclusion. As you are therefore unable to provide a 10% grading bracket for plaque deemed <50% you can just put <50% in the box. If you think the NASCET DR measurement requires further discussion or there are any caveats for the discrepancy this can be mentioned in the conclusion.

Any limitations or caveats for a mismatch between haemodynamic velocity criteria and the concluded graded stenosis (such as a contralateral occlusion, large bulb (>10mm) or thrombus) should be documented.

The CVS should write their own conclusion, using their professional clinical judgment, at the bottom of the report. The CVS should bear in mind that there may be unusual cases - e.g. recanalised thrombus in an ICA with "trickle flow" - This can be directly written into the box.

If the findings differ grossly from another modality's findings, or from a scan performed elsewhere, an immediate second opinion should be sought from another senior colleague when possible.

If the ICA stenosis is considered to be >50% and symptomatic then the referring clinician

Site(s)	Document Number	Approved	Page 9 of 9
All Sites	VAS-DP-1	Kelly Swagell	
Title		Version Date	Version Number:
Carotid and vertebral ultrasound		Dec 2021	1.2

must be contacted immediately.

If synthetic grafts, stents or patches are present they should be drawn on the diagram with dashes on the sides of the artery or graft. Grading criteria is not well established in these instances and the above grading criteria should be used with caution.

Any incidental findings should be documented and further imaging recommended when clinically appropriate.

The only exception for not using this protocol when scanning carotids is for the EVOCAR-1 trial. Their patients will continue to be scanned using the study approved (previous v 1.0) protocol VAS-DP-24 (ref 11).

References

1.	VAS-ED-3. SVT - Vascular Technology Professional Performance Guidelines Extracranial Cerebrovascular Duplex Ultrasound Examination (2021).
2.	Children's Wisconsin. 2020. Abnormalities of the head and neck arteries (Cerebrovascular Abnormalities).
3.	Osiro, S. et al. (2012). 'A review of subclavian steal syndrome with clinical correlation', <i>Medical Science Monitor</i> , 18(5), RA57-63
4.	Amin. P, Kresowik, T. Carotid Endarterectomy - Basic medical key. 2020.
5.	Oates, C.P. et al. (2009). 'Joint recommendations for reporting carotid ultrasound investigations in the united kingdom', <i>European Journal of Vascular and Endovascular Surgery</i> , 37(3), pp.251-261
6.	Howard, G. et al. (1993). 'Carotid artery intimal-medial thickness distribution in general populations as evaluated by B-mode ultrasound. ARIC Investigators', <i>Stroke</i> , 24(9), pp.1297-1304
7.	Thrush A & Hartshorne T, 2010, <i>Vascular Ultrasound: How, why and when</i> , 3rd edn, Elsevier Limited, London (pg 138).
8.	Knox RA, Breslau PJ, Strandness Jr DE. A simple parameter for accurate detection of severe carotid disease. <i>Br J Surg</i> 1982;69: 230e3.
9.	Hunink MG, Polak JF, Barlan MM, O'Leary DH. Detection and quantification of carotid artery stenosis: efficacy of various Doppler velocity parameters. <i>AmJ Roentgenol</i> 1993;160:619e25.
10.	Dhanjil S, Jameel M, Nicolaides A, Belcaro G, Williams M, Griffin M, et al. Ratio of peak systolic velocity of internal carotid to end diastolic velocity of common carotid: new duplex criteria for grading internal carotid stenosis. <i>J Vasc Technol</i> 1997;21:237e40.
11.	VAS-DP-24. Carotid (EVOCAR-1) Protocol.